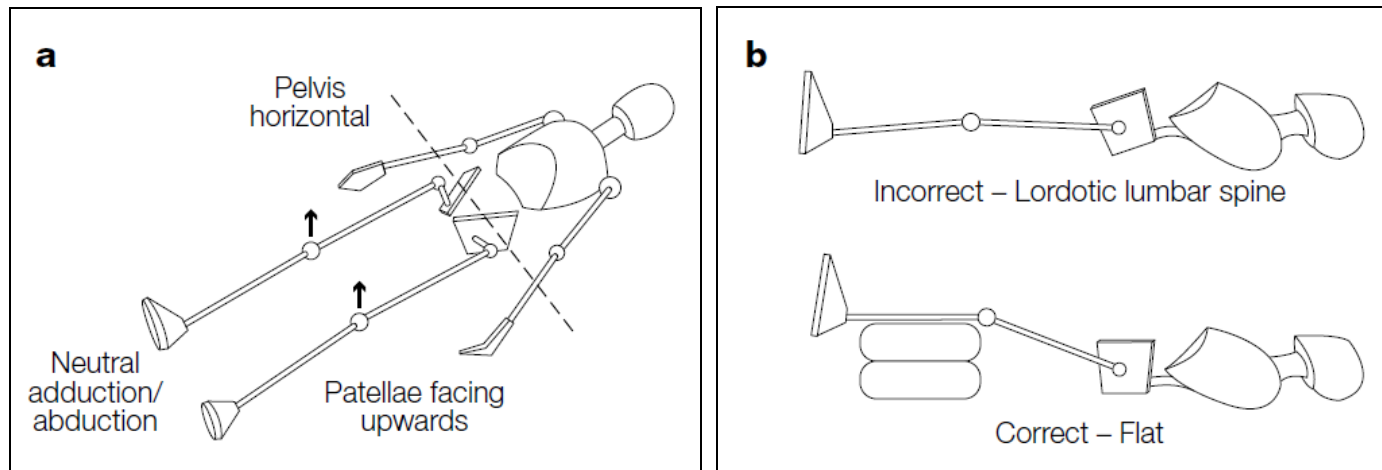


## Positioning For AP Pelvis Radiographs For Children with Cerebral Palsy and Similar Conditions



Reproduced with permission and copyright © of the British Editorial Society of Bone and Joint Surgery (Dobson F, Boyd RN, Parrott J, Nattrass GR, Graham HK. Hip surveillance in children with cerebral palsy: impact on the surgical management of spastic hip disease. *J Bone Joint Surg [Br]* 2002;84-B:720-726).

### PLEASE ENSURE THE FOLLOWING:

1. Neutral adduction/abduction of the legs
2. Neutral rotation of the legs so the patella face upwards
3. Pelvis horizontal with no pelvic tilt; flatten the lumbar spine by elevating the legs, if necessary