

Hip Surveillance Radiographs

Information for Radiology Staff

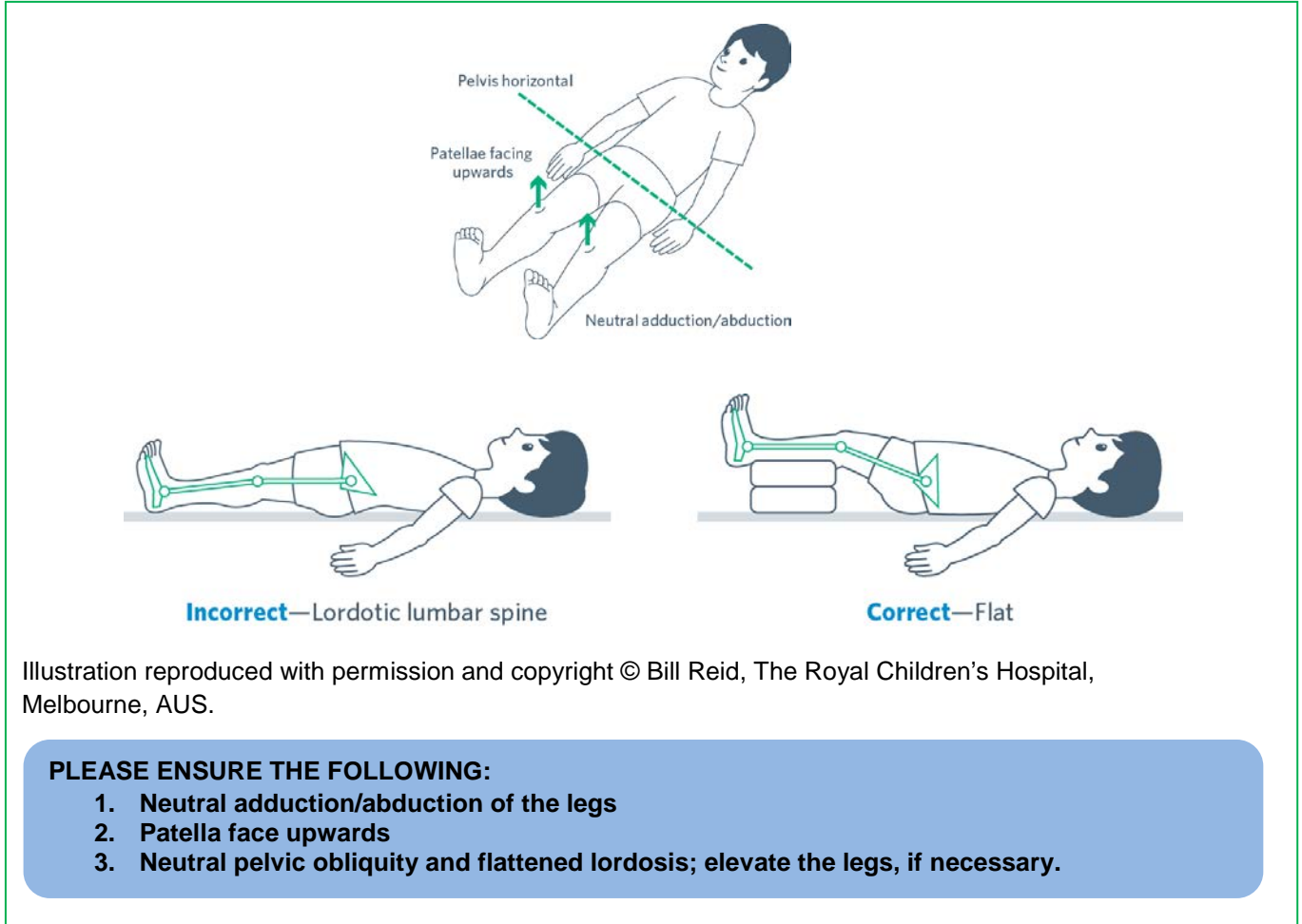


Illustration reproduced with permission and copyright © Bill Reid, The Royal Children's Hospital, Melbourne, AUS.

PLEASE ENSURE THE FOLLOWING:

1. Neutral adduction/abduction of the legs
2. Patella face upwards
3. Neutral pelvic obliquity and flattened lordosis; elevate the legs, if necessary.

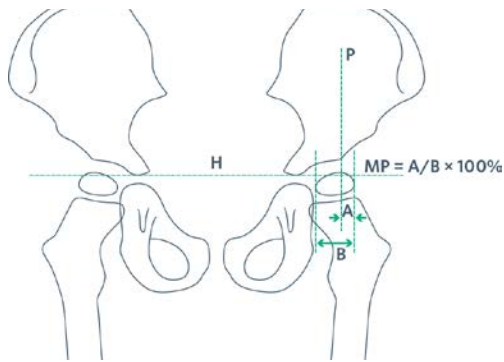
Figure 1: Positioning for AP Pelvis Radiographs for Children with Cerebral Palsy

What is the role of radiology in hip surveillance?

Hip displacement cannot be detected by clinical exam alone. Radiological monitoring is required. Children receive clinical exam and radiographs at standardized intervals based on their level of risk for displacement. The recommended radiological measure used to monitor hip displacement is migration percentage (MP). MP is defined as the percentage of the ossified femoral head outside of the lateral margin of the ossified acetabulum (Figure 2).¹

Why is positioning important?

An antero-posterior (AP) x-ray of the pelvis taken in a standardized position (Figure 1) is required to accurately measure the migration percentage and to allow for comparison of sequential radiographs.^{1,4,5} MP is affected by the amount of abduction or adduction of the leg.¹ The legs must, therefore, be positioned in a parallel position. Measurement of the MP requires that the triradiate cartilages be visible and therefore anterior and posterior pelvic tilt must be corrected. This can be done by raising the feet on pillows to flatten the lumbar spine.



Reproduced with permission from Wynter et al. Australian Hip Surveillance Guidelines for Children with CP; 2014.

Figure 2: Migration percentage as a measure of hip displacement

Measuring Migration Percentage³

MP represents the portion of the ossified femoral head that is not covered by the ossified acetabular roof.

1. Draw Hilgenreiner's line (H), a horizontal line between the superior aspect of the triradiate cartilages. When the triradiate cartilages are closed, after skeletal maturity, the most useful horizontal line is through the most inferior points of the acetabular teardrops.
2. Draw Perkin's line (P), perpendicular to Hilgenreiner's line, at the lateral edge of the acetabulum.
3. Draw lines, parallel to Perkin's line, along the medial and lateral side of the ossified femoral head.
4. Measure distance between medial and lateral sides of the femoral head (B).
5. Measure distance between Perkin's line and lateral side of the femoral head (A).
6. Calculate MP ($A/B \times 100\%$).

Field of View & Gonad Protection³

The ideal field of view will include the proximal femurs; this allows for the assessment of whether the femurs were positioned in neutral abduction/adduction, as required for measuring migration percentage (Figure 3). Local gonad protection guidelines should be used.

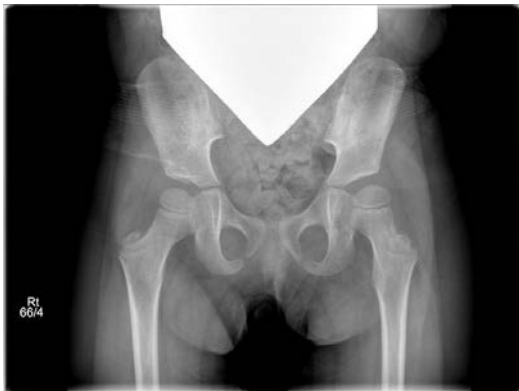

Figure 3: Optimal field of view

What is hip surveillance?

Hip surveillance is the process of identifying and monitoring critical early indicators of progressive hip displacement⁶. Programs in Sweden and Australia, together with timely orthopaedic surgery, have significantly reduced the incidence of hip dislocations in children with cerebral palsy.^{4,7,8} The **Child Health BC Hip Surveillance Program for Children with Cerebral Palsy** aims to ensure that all children with cerebral palsy receive appropriate screening and are referred to a paediatric orthopaedic surgeon at the appropriate time to minimize or prevent complications associated with hip dislocations. The program is coordinated at BC Children's Hospital and works together with a child's local healthcare team to complete hip surveillance in the child's local community. The child's local physiotherapist completes a short clinical exam and, if necessary, the child has an x-ray of their hips at their local hospital. All children with cerebral palsy throughout the province are eligible.

What is hip displacement?

Hip displacement, or subluxation, is the gradual movement of the femoral head laterally from under the acetabulum (Figure 4). One in three children with cerebral palsy will have hip displacement, with up to 90% of children that are most severely affected being effected.⁹⁻¹¹ Children with cerebral palsy are born with a normal hip. A lack of, or delay in, weight-bearing and abnormal muscle forces around the hip can contribute to changes in the proximal femur and gradual subluxation.

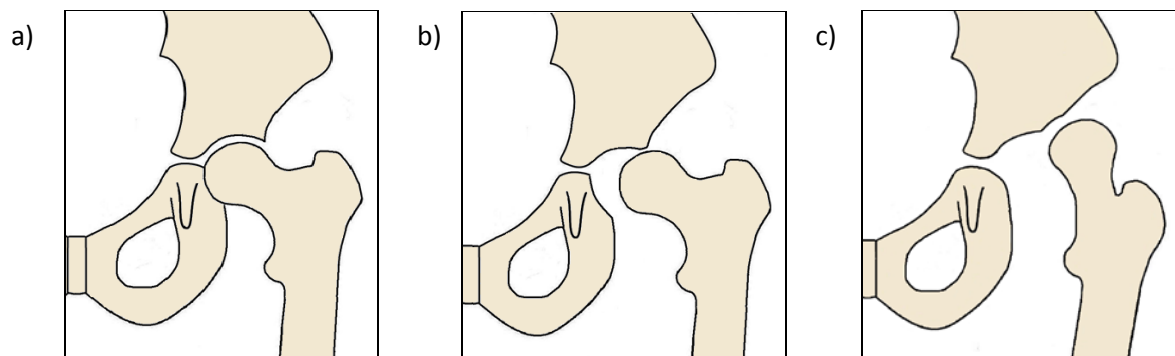


Figure 4: a) Normal hip, b) Displaced hip, c) Dislocated hip

References:

1. Reimers J. The stability of the hip in children: a radiological study of results of muscle surgery in cerebral palsy. *Acta Orthop Scand*. 1980;184:1-100.
2. Wynter M, Gibson N, Kentish M, Love SC, Thomason P, Willoughby K, Graham HK. Australian Hip Surveillance Guidelines for Children with Cerebral Palsy. 2014. Accessed 30 Oct 2017. <https://www.ausacpdm.org.au/resources/australian-hip-surveillance-guidelines/>.
3. American Academy of Cerebral Palsy and Developmental Medicine Hip Surveillance Care Pathway. (12 Sep 2017). Accessed 28 Mar 2018. <https://www.aacpdm.org/publications/care-pathways/hip-surveillance>.
4. Dobson F, Boyd RN, Parrott J, Natrass GR, Graham HK. Hip surveillance in children with cerebral palsy. Impact on the surgical management of spastic disease. *J Bone Joint Surg [Br]*. 2002; 84-B:720-726.
5. Scrutton D. The early management of hips in cerebral palsy. *Dev Med Child Neurol*. 1989;31:108-116.
6. Wynter M, Gibson N, Kentish M, Love S, Thomason P, Graham HK. The consensus statement on hip surveillance for children with cerebral palsy: Australian standards of care. *J Pediatr Rehabil Med*. 2011;4(3):183-95.
7. Hagglund G, Andersson S, Duppe H, Lauge-Pedersen H, Nordmark E, & Westbom L. Prevention of dislocation of the hip in children with cerebral palsy. The first ten years of a population-based prevention programme. *J Bone Joint Surg [Br]*. 2005;87-B:95-101.
8. Kentish M., Wynter M., Snape N., Boyd R. *Five-year outcome of state-wide hip surveillance of children and adolescents with cerebral palsy*. *J Pediatr Rehabil Med*, 2011. 4: 205–17.
9. Connelly A., Flett P., Graham H.K., Oates J. *Hip surveillance in Tasmanian children with cerebral palsy*. *J Paediatr Child Health*, 2009. 45: 437–443.
10. Hagglund G., Lauge-Pedersen H., Wagner P. Characteristics of children with hip displacement in cerebral palsy. *BMC Musculoskelet Disord*, 2007. 8: 101.
11. Soo B., Howard J.J., Boyd R.N., Reid S.M., Lanigan A., Wolfe R., Reddiough D., Graham H.K. *Hip displacement in cerebral palsy*. *J Bone Joint Surg Am*, 2006. 88: 121–29.

For more information, please visit our website at www.childhealthbc.ca/hips,
call 1-888-300-3088, extension 4099, or email hips@cw.bc.ca.